



**PATIENT**

Ginger Nachodsky

**SPECIES**

Canine

**BREED**

Labrador Mix

**SEX**

Female Spayed

**AGE**

10.28.12

**WEIGHT**

57lbs

**PRESENTING CLINICAL SIGNS**

History: Recheck echo. Presented for evaluation of oral mass and pre-dental bloodwork on 2/14/23. Persistent grade 2/6 murmur. History of osteoarthritic symptoms. Bloodwork revealed elevating liver values.

-Pertinent abnormal PE/Chem/CBC/UA Results: 2/14/23: CBC: WNL. CHEM: hypochloremia 105, elevated liver values: ALT- 267 (prev 146, 124) , AST 73 (prev 41/normal). UA: pending. T4: 2.7 WNL  
 -Current medications: Rimadyl 50mg q12-24h.

-Sedation used: Patient sedated with Torbugesic.

-Pertinent previous ultrasound results (4/2022 MML): Mild MR, no LA or LVE. LA: 2.5, LV: 3.7.

-STAT: Not requested

-Imaging performed by: Andi Parkinson, BS, RDMS.

**ECHOCARDIOGRAM FINDINGS**

2D, m-mode, color flow and doppler imaging is available. Mild diffuse thickening of mitral valve leaflets with no prolapse into the left atrial lumen. Mild mitral regurgitation with no left atrial dilation. Normal MR velocity. Normal LV diameter with adequate myocardial function. The tricuspid valve appears normal with no tricuspid regurgitation. Normal right atrial and ventricular diameter and morphology indicating no overt evidence of pulmonary arterial hypertension. The pulmonic and aortic valves are normal in morphology and mobility. Normal pulmonic and aortic outflow velocities with laminar flow. No obvious aortic or pulmonic insufficiency. No pericardial or pleural effusion noted. No obvious cardiac masses.

**CARDIAC CHART**

**INTERPRETED BY**

Maggie Machen Lamy,  
 DVM, DACVIM  
 (Cardiology)

**HOSPITAL NAME**

Perry Hall Animal  
 Hospital

**REFERRING VET**

Dr. Breidenbaugh

**INVOICE**

29286

**DATE**

2.28.23

CANINE CARDIAC PARAMETERS	MR VMAX (m/s)	TR VMAX (m/s)	LA/AO (Boon method)	LA/AO (Heart Base; Swe)	FS (%)	EF (%)	EPSS (cm)
NORMAL PARAMETER	4.5-5.5	<2.7	1.3	<1.6	28-40	40-100	<0.6
PATIENT	NM	NA	NM	1.3	41	72	NM
CANINE CARDIAC PARAMETERS	HR (BPM)	AV VMAX (m/s)	PV MAX (m/s)	BODY WEIGHT (kg)	LA 2D short axis Base view (cm)	LVIDd Avg; 2D and m-mode short axis (cm)	LVIDs Avg; 2D and m-mode short axis (cm)
NORMAL PARAMETER	50-100	0.7-1.7	0.7-1.6	BELOW	BELOW	BELOW	BELOW
PATIENT	120	2.0	1.4	25.9	2.7	3.8	2.2
*Normal chamber parameters expressed as a mean value (SD)				3	1.27 (5.3)	2.46 (2.46)	1.36 (5.5)
BODY WEIGHT DEPENDENT PARAMETERS				5	1.40 (4.5)	2.74 (5.2)	1.60 (4.7)
<i>*Note: All measurements based upon multi-modal images and methods. An average value is reported.</i>				10	1.50 (3.8)	3.27 (3.5)	2.06 (3.1)
				15	1.83 (2.0)	3.71 (2.4)	2.43 (2.1)
				20	2.02 (1.9)	4.14 (2.2)	2.80 (2.0)
				25	2.18 (2.4)	4.48 (2.9)	3.10 (2.5)
				30	2.33 (3.3)	4.83 (3.9)	3.39 (3.4)
				35	2.48 (4.3)	5.17 (5.0)	3.69 (4.5)
				40	2.62 (5.2)	5.48 (6.1)	3.96 (5.4)
				50	2.88 (7.1)	6.07 (8.3)	4.46 (7.4)

Adapted from June Boon, Veterinary Echocardiography, 1998  
 Rishniw M and Hollis NE, J Vet Intern Med 2000; 14:429-435  
 Hansson et al, Vet Rad and Ultrasound 2002  
 Bonagura et al. Echocardiography: principles of interpretation, Vet Clin North Am 15:1177, 1995

## INTERPRETATION OF THE FINDINGS & FURTHER RECOMMENDATIONS

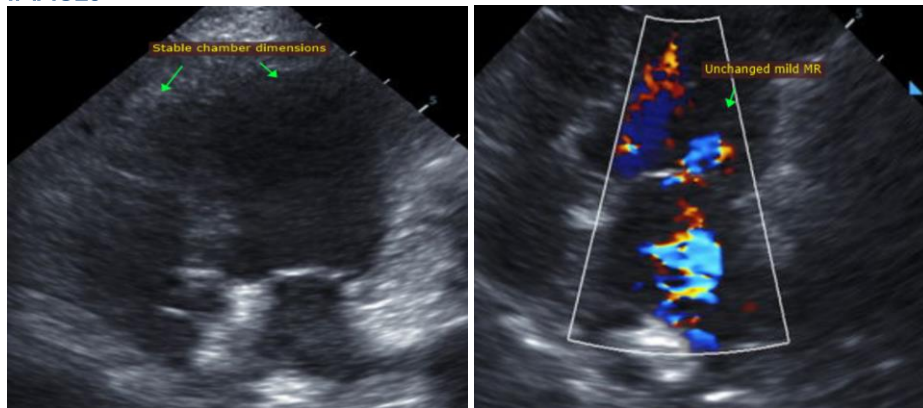
Compared to the prior study, findings appear similar. Mild mitral regurgitation appears similar without progressive left heart enlargement. A mildly elevated aortic outflow velocity is a new finding, which is a benign flow abnormality. This can be exacerbated by heart rate or volume changes. No additional issues are identified.

Given these findings, no cardiac medications are clearly indicated. Assessment of progression in the future will help predict long term prognosis, which is highly variable at this stage (B1). Omega fatty acid supplementation and mild salt restriction may be of some long-term benefit. Monitor for development of a cough, labored breathing, exercise intolerance or collapse episodes.

Anesthetic risk is considered mild if needed. Cardiac protective drug choices (opioid/benzodiazepine premedication, propofol or alfaxalone induction, isoflurane gas) are recommended. Pre-oxygenate for 5-10 minutes prior to induction. Monitor for arrhythmias, hypotension, and hypoxia both intra and post-operatively and intervene as necessary. Mild IV fluid restriction is recommended to avoid fluid overload. Avoid heart rate stimulating drugs such as atropine unless clinically indicated.

Recommend conservative monitoring with a recheck echocardiogram in 6-12 months, sooner if any development of clinical signs.

## IMAGES



**The information and recommendations provided are based on the images presented by the referring veterinarian. No evaluation can be communicated regarding pathology that was not visible in the image/video clips provided.**

Thank you for this referral. This report was generated using transcription software, and minor dictation errors may be present. If the clinical or image interpretation does not parallel your findings or if I can be of any further assistance please contact me.

**Maggie Machen Lamy, DVM**  
**Diplomate of the American College of Veterinary Internal Medicine (Cardiology)**  
**info@sonopath.com**